

An Experience with Intestinal Crohn's Disease- a Case Report

Garga Basu, Souvik Saha and Sourav Mondal:

Medical College & Hospital, Kolkata

Abstract: India nurtures a large population of Tuberculosis unlike Crohn's which is mainly a disease of Western population. Clinicopathological similarity between these two diseases often creates a dilemma and divert the physician from choosing the right path of healing. Besides Tuberculosis, being endemic in India, we often misdiagnose the cases of Crohn's as TB and thereby complicating the overall scenario. In our case report, we are showing three such cases of Crohn's misdiagnosed pre-operatively as tuberculosis, thus hampering the proper management and treated surgically. Cases of crohn's are now increasing in India especially in the last two decades. The purpose of this publication is, to report, thus creating an awareness among caregivers to diagnose these types of cases, keeping both Crohn's and Tuberculosis in mind so as not only to execute a proper plan of management but also to alleviate the sufferings of the patients at its minimum.

I. Introduction:

The first report of 'regional ileitis' or Crohn's disease (CD) was published in 1932 [1]. In India, CD was considered almost nonexistent till 1986 [2]. During the last 10 years, CD is being reported more frequently from different parts of India.

Crohn's disease is a multisystem group of disorders characterized by focal, asymmetric, transmural, and, occasionally, granulomatous inflammation primarily affecting the gastrointestinal tract, often fistulisation with systemic and extra-intestinal complications that can affect any age group, but onset is most common in second and third decades of life.

Tuberculosis, a very common disease in India with its various presentations, almost exclusively mimics Crohn's in respect to clinical presentation, investigations and also histopathology. But the management of these two entities differ poles apart.

So, keeping in mind the increasing prevalence of both these diseases in India, a definite diagnosis should be established for execution of a proper management pathway.

II. Case Reports

Case 1:

A 24 years lady presented with recurrent episodes of subacute intestinal obstruction associated with malaise, weight loss and weakness. Examination revealed an ill defined mass (3×3) cm at right iliac fossa while investigations showed a negative Chest X-ray and Sputum for AFB with a positive Mantoux of 18mm. BMFT showed obtuse ileocaecal angle with pulled-up caecum (Figure. 1).

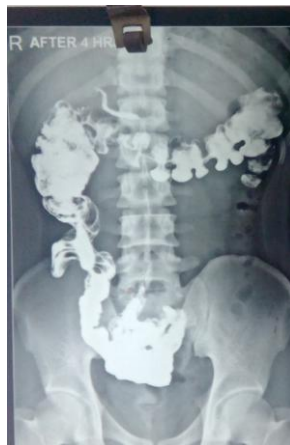

Figure.1: BMFT showing obtuse ileocaecal angle with pulled-up caecum.

Colonoscopy revealed active ulceration and nodule at ileocaecal region with deformed ileocaecal valve with ileal stricture (Figure. 2) with a biopsy reported as granulomatous inflammation.

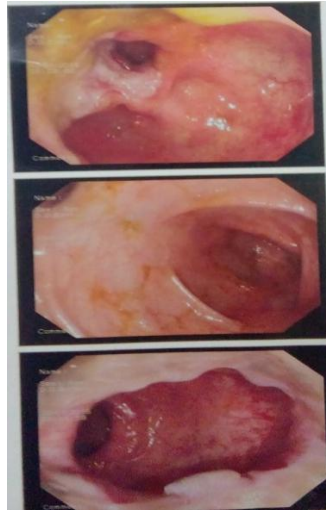


Figure.2: Colonoscopy

Patient was put on ATD but remained unresponsive to medical therapy therefore compelling surgery obvious. Intraoperatively, ileocaecal mass with enlarged mesenteric lymph node found and limited ileo-caecal resection with ileo-ascending anastomosis was done. On histopathology report, extensive circumferential fat wrapping with complete transmural inflammation, cobble stone appearance and non caseating granuloma with langerhans giant cell found, suggestive of Crohn's disease (Figure. 3). Histopathology of lymph node shows reactive hyperplasia. We put the patient initially on steroid and mesalamine and close follow up.

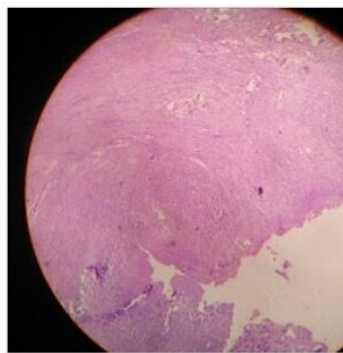


Figure.3: Histopathology of Crohn's disease (Case:1)

Case 2:

A 22 years lady presented with acute appendicitis, appendectomy was done. After one month of operation patient developed entero-cutaneous fistula. Colonoscopy, CECT of abdomen (Figure. 4) and BMFT failed to reach any definitive diagnosis except ceco-cutaneous fistula. Tuberculosis was excluded by negative sputum for AFB, Mantoux and Chest x-ray. After initial stabilization, limited ileo-caecal resection with ileoascending anastomosis was done . Histopathology showed fat wrapping, noncaseating granulomatous inflammation with langerhans cell , suggestive of crohns disease (Figure. 5). Patient was put on steroid and mesalamine and on regular follow up. Unfortunately after 15 month, patient presented with enetocutaneous fistula again. This time patient was put on steroid and infliximab. After one month of therapy, fistula output decreases and after 6 months of therapy full response was seen and patient is now in follow up.

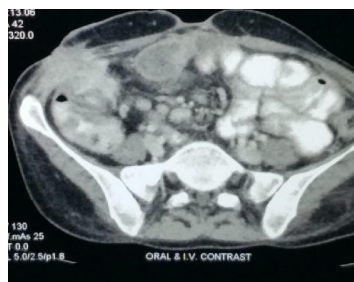

Figure.4: CECT whole abdomen showing caeco-cutaneous fistula

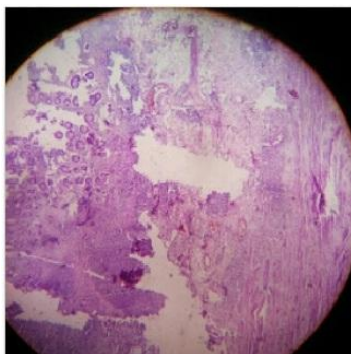


Figure.5: Histopathology of Crohn's disease (Case: 2)

Case 3:

An 18 year old gentleman presented with subacute intestinal obstruction and right iliac fossa mass along with low grade fever with evening rise of temperature, malaise and loss of appetite. On BMFT, pulled up caecum with obtuse ileocaecal angle was found with Positive Mantoux and Negative sputum for AFB. On colonoscopy, ileo-caecal stricture with nodule found, biopsy shows granulomatous inflammation. Initial diagnosis was ileocaecal tuberculosis and the patient was put on ATD but failed to respond. Limited ileocaecal resection was done with histopathology disclosing non caseating granulomatous inflammation with langerhans giant cell and reactive hyperplasia of mesenteric lymph node suggestive of Crohn's disease. So, we put the patient on steroid and mesalamine and close follow up.

III. Discussion

Incidence of Crohn's disease is now in rise in India, probably due to civilization, migration of people, environmental factors, infective origin and genetic factors as well. Clinicopathological similarity of crohn's disease and tuberculosis makes the diagnosis of Crohn's difficult and radiological evidences not always support the aforesaid diagnosis.

In present days, availability of different investigations, imaging studies like colonoscopy-ileoscopy, small bowel enteroscopy, serological markers such as anti-Saccharomyces cerevisiae antibody (ASCA) for Crohn's and molecular diagnostic techniques (polymerase chain reaction), nucleic acid amplification for tuberculosis in tissue, have added benefit to diagnose CD [5]. Therefore, the rarity of CD in the past was possibly due to limited diagnostic facilities and/or lack of awareness. Besides, reduction in the frequency of childhood infections has correlated with increase in autoimmune and allergic disorders in India like Crohn's [6,7].

The distinction between Crohn's and Tuberculosis is important for proper and early plan of management. Clinical features like fever (in favor of tuberculosis), bleeding per rectum and diarrhea (both in favor of CD), and duration of symptoms (significantly longer in CD than tuberculosis) may give some clue but not useful in all cases. Segmental colonoscopic biopsies are often useful in the differentiation of ileocaecal tuberculosis from CD that has also failed to diagnose the aforesaid reported cases. The salient features of CD are small noncaseating granulomatous inflammation with Langerhans' giant cell, focally enhanced colitis, pericryptal granulomatous inflammation and the presence of architectural alteration that did not show granulomatous response in the same or adjacent segments. Even a pre-operative ASCA titre is not specific for CD too [9]. Therefore, serious efforts should be made to exclude abdominal tuberculosis before making sure that the patient is having CD [8].

Regarding treatment options, steroids and mesalamine are most commonly used leaving Infiximab and Adalimumab to be used in refractory and intolerant cases of Crohn's. Various medical therapies, including antibiotics, immunomodulators (azathioprine, 6-mercaptopurine, cyclosporine) and total parenteral nutrition (TPN), have been used to treat this condition. Surgery is avoided as far as possible to prevent complications like intestinal fistulae and recurrence [10].

Therefore, proper management cannot be started timely so, sufferings of patients are increased as supported by our case report too. A pre-operative diagnosis of crohn's is thus essential not only to avoid unnecessary surgical exercise for a surgeon but also for the sake of a suffering soul. In all the reported cases, characteristic skip lesion and other features were absent on colonoscopy leaving post-opreative histopathology as the only evidence of Crohn's. So, surgery should be avoided to minimum before a definite diagnosis is reached either to exclude Tuberculosis or to suggest Crohn's disease.

IV. Conclusion

Clinical similarity often produces diagnostic dilemma that hampers timely diagnosis and proper management of CD and complicates the condition of the patients. CD should be kept in mind along with TB. A proper pre-operative diagnosis is essential for management of such cases. Unnecessary surgery in Crohn's not only exposes a patient to high surgical risk profile but also invites a miserable post-operative life ahead. So, these cases should be dealt with utmost expertise for establishing a proper and definite diagnosis so as to leave surgery as the last resort in the management plan.

V. List Of Abbreviations:

- CD- Crohn's Disease
- TB- Tuberculosis
- BMFT- Barium Meal Follow Through
- AFB- Acid fast Bacilli
- ATD- Anti-Tubercular Drug

References

- [1]. Crohn BB, Ginzburg L, Oppenheimer GD. Regional ileitis, pathological and clinical entity. JAMA 1932;99:1923-9.
- [2]. Antia FP. Crohn's conundrum in Indians. Indian J Gastroenterology;1986;5:79-80.
- [3]. Das P, Shukla HS. Clinical diagnosis of abdominal tuberculosis; Br J Surg 1976;63:941-6.
- [4]. Kapoor VK. Abdominal tuberculosis: the Indian contribution. Indian J Gastroenterol 1998;17:141-7.
- [5]. Amarpurkar DN, Patel ND, Amarpurkar AD, Agal S, Baigal R, Gupte P. Tissue polymerase chain reaction in diagnosis of intestinal tuberculosis and Crohn's disease. J Assoc Physicians India 2004;52:863-7.
- [6]. Bach JF. The effect of infections on susceptibility to autoimmune and allergic diseases. N Engl J Med 2002;307:911-20
- [7]. Weiss ST. Eat dirt – the hygiene hypothesis and allergic diseases. N Engl J Med 2002;347:930-1.
- [8]. Kapoor VK. Koch's or Crohn's? Int J Clin Pract. 1997; 51:246-7.
- [9]. Ghoshal UC, et al. Anti-Saccharomyces cerevisiae antibody is not useful to differentiate between Crohn's disease and intestinal tuberculosis in India. J Postgrad Med. 2007; 53:166-70.
- [10]. Hanauer SB, Sandborn WJ, Rutgeerts P, Fedorak RN, Lukas M, MacIntosh D, Panaccione R, Wolf D, Pollack P: Human anti-tumor necrosis factor monoclonal antibody (adalimumab) in Crohn's disease: the CLASSIC-I trial. Gastroenterology 2006, 130:323-333.